



# Five-Year Follow-up of Nonfibrotic Scars in the Comparison of Age-Related Macular Degeneration Treatments Trials

Ebenezer Daniel, MBBS, PhD,<sup>1</sup> Gui-shuang Ying, PhD,<sup>1</sup> Benjamin J. Kim, MD,<sup>1</sup> Cynthia A. Toth, MD,<sup>2</sup> Frederick Ferris III, MD,<sup>3</sup> Daniel F. Martin, MD,<sup>3,4</sup> Juan E. Grunwald, MD,<sup>1</sup> Glenn J. Jaffe, MD,<sup>2</sup> Joshua L. Dunaief, MD, PhD,<sup>1</sup> Wei Pan, MS,<sup>1</sup> Maureen G. Maguire, PhD,<sup>1</sup> for the Comparison of Age-Related Macular Degeneration Treatments Trials

**Purpose:** To describe changes in visual acuity (VA) and macular morphologic features at 5 years in eyes with nonfibrotic scar (NFS) identified at 1 year in the Comparison of Age-Related Macular Degeneration Treatments Trials (CATT).

**Design:** Prospective cohort study within a randomized clinical trial.

**Participants:** Participants in CATT.

**Methods:** Participants assigned to ranibizumab or bevacizumab and to 1 of 3 dosing regimens were released from the clinical trial protocol after 2 years and recalled at 5 years. Nonfibrotic scar was identified on color images at year 1 as flat, small, well-circumscribed areas of pigmentation with varying degrees of central hypopigmentation without exposure of underlying choroidal vessels at the site of baseline choroidal neovascularization. Follow-up images were assessed for changes in and around NFS.

**Main Outcome Measures:** Pigmentation changes, VA, development of fibrotic scar (FS), nongeographic atrophy (NGA), geographic atrophy (GA), retinal fluid on OCT, and fluorescein leakage.

**Results:** Among 474 eyes with images obtained at 1, 2, and 5 years, 39 (8.2%) showed NFS at 1 year with a mean VA of 80 letters (Snellen equivalent, 20/25). Among these eyes, FS developed in 5% at 2 years and 28% at 5 years. Nongeographic atrophy was observed in 34%, 47%, and 65% of eyes at 1, 2, and 5 years, respectively. Geographic atrophy developed in 5% of eyes at 2 years and 21% at 5 years. Among eyes with NFS, FS, or no scar at 1 year, mean VA at 5 years was 73 letters (20/32), 48 letters (20/100), and 62 letters (20/63), respectively. At 5 years, NFS eyes demonstrated less GA, less intraretinal fluid, more subretinal fluid, and less subretinal pigment epithelium fluid (all  $P < 0.01$ ). Among NFS eyes, mean thickness of the retina, subretinal tissue complex, and total retina did not change across years 1 to 5 ( $P > 0.50$ ). The proportion of eyes with fluid on OCT also did not change ( $P = 0.36$ ). Subretinal hyperreflective material disappeared by 5 years in 40% of eyes with NFS.

**Conclusions:** These results indicate that, on average, eyes with NFS after anti-VEGF treatment have good VA not only at 1 and 2 years, but also through 5 years. *Ophthalmology* 2019;126:743-751 © 2018 by the American Academy of Ophthalmology

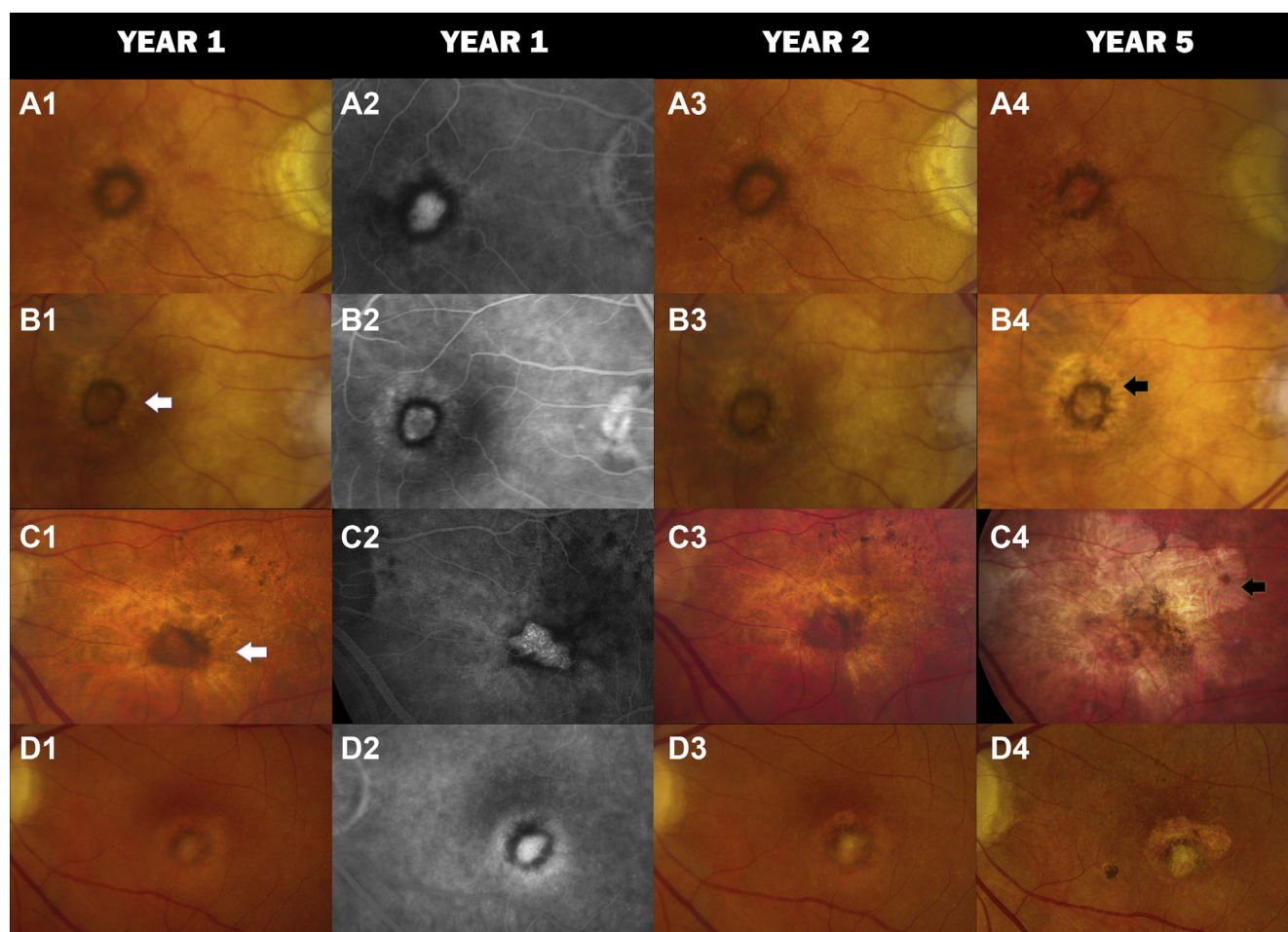


Supplemental material available at [www.aaojournal.org](http://www.aaojournal.org).

Treatment of neovascular age-related macular degeneration (nAMD) with intravitreal anti-vascular endothelial growth factor (VEGF) is well established and is associated with improvement in visual acuity (VA) during the first 2 years for most patients.<sup>1-5</sup> However, with continued follow-up, VA often declines and the presence and area of scarring and macular atrophy increases.<sup>6-11</sup>

The morphologic appearance at the site of nAMD after anti-VEGF treatment has been described in reports from several clinical trials of anti-VEGF treatment.<sup>12-17</sup> Quantitative measurements and qualitative descriptions, mainly of macular atrophy and fibrotic scar (FS), derived from multiple imaging methods have provided a greater understanding of the pathologic processes and their progression

over time. However, nonfibrotic scar (NFS) may be a unique sequela of anti-VEGF therapy that has not been investigated fully. Nonfibrotic scar is identified on color images as a flat, small, well-circumscribed area of pigmentation with varying degrees of central hypopigmentation and with corresponding features on fluorescein angiograms.<sup>18,19</sup> In the Comparison of Age-Related Macular Degeneration Treatments Trials (CATT), NFS developed in 21% of treated eyes by 2 years, with 13% in the first year.<sup>18</sup> In this article, we describe the morphologic changes that occur at 2 and 5 years in and around NFS that had developed by 1 year after initiation of anti-VEGF therapy for nAMD in the study eyes of participants in CATT and the CATT Follow-up Study.



**Figure 1.** Color fundus photograph (CFP) and fluorescein angiography (FA) images of nonfibrotic scar (NFS) in 4 different Comparison of Age-Related Macular Degeneration Treatments Trials participants. **A1**, Typical NFS at year 1 with hyperpigmentation encircling an area of hypopigmentation on CFP. **A2**, Corresponding FA image showing an inner hyperfluorescence surrounded by circular hypofluorescence. No changes are seen (**A3**) at year 2, but (**A4**) part of the pigmentation at 7 o'clock has disappeared in the year 5 CFP. **B1**, **B2**, Halo of nongeographic atrophy (NGA) surrounding the NFS in year 1. This persists (**B3**) in year 2 and (**B4**) intensifies into geographic atrophy (GA) at year 5. **C1–C3**, Nongeographic atrophy surrounding the NFS at years 1 and 2 with (**C4**) development of a large GA at year 5 and the disappearance of more than half of the circular hyperpigmentation of the NFS. **D1**, **D2**, Nonfibrotic scar that (**D3**) developed fibrosis within the hyperpigmented ring at year 2 (**D4**) that is more pronounced at year 5. Some amount of fibrosis also is observed superiorly overlying an area of GA. White arrow = NGA; black arrow = GA.

## Methods

Details of the methods used in CATT and CATT Follow-up Study have been described previously.<sup>1,8,14,20,21</sup> Key features relevant to this report are summarized below.

### Enrollment of Participants

Participants in CATT (n = 1185) enrolled in the clinical trial through 43 clinical centers in the United States between February 2008 and December 2009. Study eyes had untreated active (leakage on fluorescein angiography [FA] and fluid on OCT) choroidal neovascularization (CNV) associated with age-related macular degeneration. Either CNV or fluid was required to be present at the foveal center. Patients were excluded if scar involved the foveal center, but eyes with NFSs with an area of less than 50% of the total CNV lesion area were allowed. Participants were assigned randomly to treatment with intravitreal injections of ranibizumab or bevacizumab and to 1 of 3 dosing regimens for the initial 2 years of the study: monthly injections, monthly evaluation

with injection only when signs of active neovascularization were present (pro re nata [PRN]), or monthly injections for 1 year followed by PRN injections for 1 year. Institutional review boards associated with each center approved the study, and written informed consent was obtained from all participants. All research adhered to the tenets of the Declaration of Helsinki. The complete list of IRBs are from the participating institutions listed in the CATT credit roster (available at [www.aaojournal.org](http://www.aaojournal.org)). The study complied with Health Insurance Portability and Accountability Act regulations. The CATT was registered with [ClinicalTrials.gov](http://ClinicalTrials.gov) (identifier, NCT00593450).

### Follow-up of Participants

Color fundus photographs (CFPs), FA images, OCT images, and VA measurements were obtained at baseline and 1, 2, and 5 years. At 2 years, participants were released from the clinical trial protocol and were managed according to best medical judgment. The CATT participants who were alive at the end of the clinical trial (n = 1117) were targeted to participate in the CATT Follow-up

Table 1. Morphologic Characteristics at 1, 2, and 5 Years in 39 Eyes with Nonfibrotic Scar at 1 Year

Characteristics on Color Fundus Photographs and Fluorescein Angiograms	Year, No. (%)			P Value
	1	2	5	
Nonfibrotic scar, yes (%)	39 (100)	39 (100)	39 (100)	—
Fibrotic scar, yes (%)	0 (0)	2 (5)	11 (28)	0.004
Geographic atrophy, yes (%)	0 (0)	2 (5)	8 (21)	0.02
Nongeographic atrophy, yes (%)	11 (34)	18 (47)	24 (65)	0.04
Leakage on angiography, yes (%)	18 (50)	11 (29)	7 (20)	0.02
OCT characteristics				
Any fluid, yes (%)	24 (65)	28 (72)	30 (77)	0.36
Intraretinal fluid, yes (%)	13 (35)	14 (36)	16 (41)	0.78
Subretinal fluid, yes (%)	15 (42)	20 (51)	20 (51)	0.42
Sub-retinal pigment epithelium fluid, yes (%)	8 (28)	10 (29)	9 (23)	0.54
Retinal thickness (μm), mean (SD)	165 (39)	168 (52)	163 (56)	0.67
Subretinal fluid thickness (μm), mean (SD)	5.7 (17)	8.9 (21)	7.0 (26)	0.61
Subretinal tissue complex thickness (μm), mean (SD)	91.1 (68)	94.7 (68)	97.8 (78)	0.77
Total retinal thickness (μm), mean (SD)	261 (78)	272 (88)	271 (94)	0.56
Subretinal hyperreflective material, yes (%)	16 (44)	14 (37)	19 (49)	0.39

— = not applicable; SD = standard deviation.

Study at approximately 5 years after initiation of the anti-VEGF therapy. A total of 203 of these patients died between year 2 and the close of the examinations for the CATT Follow-up Study, leaving 914 available for the year 5 visit.

### Assessment of Images

Digital CFPs, FA images, and OCT scans were graded applying the same methods in all years.<sup>20</sup> Briefly, dual-reader grading was performed on each image set for various morphologic features by trained and certified CATT readers masked to demographic and clinical details. Color fundus photographs and FA images were

evaluated at the Scheie Ophthalmology Reading Center, University of Pennsylvania, Philadelphia, Pennsylvania, whereas OCTs were evaluated at the Duke Reading Center, Duke University, Durham, North Carolina.<sup>21</sup> Grading was performed on CFPs and FA images to identify fluorescein leakage, CNV type (occult, minimally classic, and predominantly classic), hemorrhage, serous pigment epithelial detachment, blocked fluorescence, FS, NFS, nongeographic atrophy (NGA), geographic atrophy (GA), and retinal pigment epithelium (RPE) tear. Morphologic features from both eyes at and away from the foveal center were identified. Discrepancies on grading results were adjudicated between the readers and the director of the reading center (E.D.),

Table 2. Morphologic Characteristics in Color Fundus Photographs at 1, 2, and 5 Years in Eyes with No Scar, Nonfibrotic Scar, Fibrotic Scar, and No Scar at Year 1

Characteristics on Color Fundus Photographs and Fluorescein Angiograms	Scar Group	Year, No. (%)			P Value*
		1	2	5	
Geographic atrophy, yes (%)	No scar (n = 367)	83 (23)	95 (26)	166 (45)	<0.0001
	Nonfibrotic scar (n = 39)	0 (0)	2 (5)	8 (21)	0.02
	Fibrotic scar (n = 68)	12 (18)	16 (24)	37 (54)	<0.0001
	P value†	0.0004	0.008	0.002	
Nongeographic atrophy, yes (%)	No scar (n = 367)	137 (42)	167 (46)	235 (72)	<0.0001
	Nonfibrotic scar (n = 39)	11 (34)	18 (47)	24 (65)	0.04
	Fibrotic scar (n = 68)	30 (49)	33 (50)	43 (73)	0.009
	P value†	0.36	0.79	0.61	
Leakage on angiography, yes (%)	No scar (n = 367)	162 (45)	120 (33)	79 (25)	<0.0001
	Nonfibrotic scar (n = 39)	18 (50)	11 (29)	7 (20)	0.02
	Fibrotic scar (n = 68)	28 (43)	15 (23)	13 (22)	0.006
	P value†	0.81	0.24	0.84	
CNV lesion size (mm <sup>2</sup> ), mean (SD)	Nonfibrotic scar (n = 39)	2.6 (3.2)	3.4 (4.3)	5.8 (7.2)	0.04
	Fibrotic scar (n = 68)	10.5 (9.4)	10.4 (8.8)	17.1 (12.0)	<0.0001
	No scar (n = 367)	6.9 (6.7)	7.7 (7.3)	12.5 (10.8)	<0.0001
	P value†	<0.0001	<0.0001	<0.0001	

CNV = choroidal neovascularization; SD = standard deviation.

\*For the comparison of difference among 3 time points within a given scar group.

†For the comparison of difference among 3 scar groups.

Table 3. Fluid in OCT at 1, 2, and 5 Years in Eyes with Nonfibrotic Scar, Fibrotic Scar, and No Scar at Year 1

OCT Characteristics	Scar Group	Year, No. (%)			P Value*
		1	2	5	
Any fluid, yes (%)	No scar (n = 367)	254 (70)	278 (76)	304 (83)	<0.0001
	Nonfibrotic scar (n = 39)	24 (65)	28 (72)	30 (77)	0.36
	Fibrotic scar (n = 68)	45 (67)	55 (81)	58 (85)	0.03
	P value†	0.78	0.57	0.54	
Intraretinal fluid, yes (%)	No scar (n = 367)	160 (45)	171 (48)	212 (58)	<0.0001
	Nonfibrotic scar (n = 39)	13 (35)	14 (36)	16 (41)	0.78
	Fibrotic scar (n = 68)	41 (62)	50 (76)	55 (81)	0.02
	P value†	0.01	<0.0001	<0.0001	
Subretinal fluid, yes (%)	No scar (n = 367)	117 (33)	144 (40)	144 (40)	0.008
	Nonfibrotic scar (n = 39)	15 (42)	20 (51)	20 (51)	0.42
	Fibrotic scar (n = 68)	14 (22)	16 (25)	21 (32)	0.33
	P value†	0.10	0.02	0.16	
Sub-RPE fluid, yes (%)	No scar (n = 367)	128 (40)	156 (45)	151 (42)	0.12
	Nonfibrotic scar (n = 39)	8 (28)	10 (29)	9 (23)	0.54
	Fibrotic scar (n = 68)	10 (19)	14 (24)	17 (26)	0.51
	P value†	0.005	0.003	0.007	

RPE = retinal pigment epithelium.

\*For the comparison of difference among 3 time points within a given scar group.

†For the comparison of difference among 3 scar groups.

and unresolved discrepancies were reviewed by the principal investigator (J.E.G.) to complete a final consensus grading form. OCT scan features that were graded included the location of fluid (intraretinal, subretinal, and sub-RPE); thickness at the foveal center of the retina, subretinal fluid, and subretinal tissue complex; presence of subretinal hyperreflective material (SHRM); RPE elevation; epiretinal membrane; and vitreomacular attachment. Dual-reader grading of OCT discrepancies was arbitrated by a third, independent senior reader.

### Assessment of Nonfibrotic Scar

An ophthalmologist (E.D.) evaluated 1-year CFPs and FA images to identify NFS among CATT participants for whom all 3 follow-up

visits (1, 2, and 5 years) images were available. Nonfibrotic scars typically were flat, small, well-circumscribed areas of pigmentation with varying degrees of central hypopigmentation on CFPs (Fig 1). The peripheral pigmentary changes in these scars often followed the outline of previously active CNV lesion. The hypopigmented areas were flat and choroidal vessels were not visible. Hyperfluorescence of the depigmented area appeared early on FA and persisted or increased in intensity in the late phase. Hypofluorescence on FA surrounding the hyperfluorescence corresponded to the pigmented borders observed on CFPs.<sup>18</sup>

Nonfibrotic scars were distinguished from FSSs, which were identified on color stereo images as white or yellow mounds of fibrous-appearing tissue that were well defined in shape and appeared solid and on FA showed either hyperfluorescence resulting from

Table 4. Thickness of OCT Characteristics at 1, 2, and 5 Years in Eyes with Nonfibrotic Scar, Fibrotic Scar, and No Scar at Year 1

OCT Feature Thickness (µm)	Scar Group	Year, Mean (Standard Deviation)			P Value*
		1	2	5	
Retinal thickness	No scar (n = 367)	156 (53)	156 (56)	144 (85)	0.007
	Nonfibrotic scar (n = 39)	165 (39)	168 (52)	163 (56)	0.67
	Fibrotic scar (n = 68)	161 (84)	159 (91)	162 (156)	0.98
	P value†	0.63	0.51	0.25	
Subretinal fluid thickness	No scar (n = 367)	7.4 (26)	9.4 (39)	5.9 (22)	0.32
	Nonfibrotic scar (n = 39)	5.7 (17)	8.9 (21)	7.0 (26)	0.61
	Fibrotic scar (n = 68)	8.3 (32)	3.9 (19)	1.3 (11)	0.13
	P value†	0.90	0.50	0.24	
Subretinal tissue complex thickness	No scar (n = 367)	127 (117)	127 (111)	107 (101)	0.0005
	Nonfibrotic scar (n = 39)	91 (68)	95 (68)	98 (78)	0.77
	Fibrotic scar (n = 68)	178 (102)	157 (97)	98 (81)	<0.0001
	P value†	0.0002	0.01	0.75	
Total retinal thickness	No scar (n = 367)	290 (141)	293 (138)	258 (138)	<0.0001
	Nonfibrotic scar (n = 39)	261 (78)	272 (88)	271 (94)	0.56
	Fibrotic scar (n = 68)	347 (144)	320 (144)	278 (191)	0.02
	P value†	0.003	0.18	0.62	

\*For the comparison of difference among 3 time points within a given scar group.

†For the comparison of difference among 3 scar groups.



Table 5. Visual Acuity over Time in Eyes in Which Nonfibrotic Scar, Fibrotic Scar, and No Scar Developed at Year 1

Status at Year 1	Visual Acuity	Year				P Value*
		0	1	2	5	
Nonfibrotic scar (n = 39)	≥20/20, no. (%)	0 (0)	19 (49)	12 (31)	7 (18)	<0.0001
	20/25–20/40, no. (%)	18 (46)	19 (49)	20 (51)	21 (54)	
	≤20/50, no. (%)	21 (54)	1 (3)	7 (18)	11 (28)	
	Mean (SD), letters	66 (9)	80 (9)	77 (8)	73 (11)	
Fibrotic scar (n = 68)	≥20/20, no. (%)	0 (0)	7 (10)	9 (13)	4 (6)	<0.0001
	20/25–20/40, no. (%)	12 (18)	25 (37)	22 (32)	17 (25)	
	≤20/50, no. (%)	56 (82)	36 (53)	37 (54)	47 (69)	
	Mean (SD), letters	54 (15)	61 (21)	63 (18)	48 (27)	
No scar (n = 367)	≥20/20, no. (%)	0 (0)	73 (20)	74 (20)	43 (12)	<0.0001
	20/25–20/40, no. (%)	181 (49)	207 (56)	201 (55)	162 (44)	
	≤20/50, no. (%)	186 (51)	87 (24)	92 (25)	161 (44)	
	Mean (SD), letters	65 (12)	73 (14)	72 (15)	62 (23)	
P value						
Mean VA among 3 groups		<0.0001	<0.0001	<0.0001	<0.0001	
Mean VA, nonfibrotic scar group vs. no scar group		0.66	0.002	0.04	0.006	

SD = standard deviation; VA = visual acuity.

\*Mean VA in each group over time.

tissue staining or blocked fluorescence of the underlying choroid. They were also differentiated from NGA, defined as area(s) of pigment disturbances including hypopigmentation and hyperpigmentation that typically corresponded to hyperfluorescence and hypofluorescence on FA in areas contiguous or previously occupied by CNV. The hypopigmented areas of NGA do not meet the criteria for GA that include sharp borders and visible choroidal vessels. Nonfibrotic scars could occur alone or along with other morphologic features. All identified NFSs at 1 year by the ophthalmologist were subjected to further independent evaluation by a retina specialist (B.J.K.), and eyes with indeterminate NFS were excluded (2.5%). Year 2 and 5 images were evaluated for the presence of NGA, GA, or FS involving or contiguous to the year-1 NFS. Active CNV and pigmentation changes in and around the NFS also were documented.

### Statistical Analysis

We performed descriptive analyses for VA change over time; incidence of FS, NGA, and GA over time; presence of active CNV; and hyperpigmentation changes over time, with mean (standard deviation [SD]) for continuous measures and proportion for categorical measures. We used the analysis of variance for comparison of continuous measures and the Fisher exact test for comparison of

proportions among scar groups. We used generalized linear models for repeated measures for evaluating change in morphologic characteristics over time (years 1, 2, and 5) for eyes in each scar group. All statistical analyses were performed with SAS software version 9.4 (SAS Institute, Inc., Cary, NC). *P* values less than 0.05 were considered to be statistically significant.

### Results

Among the 474 participants for whom photographic images were available from all 3 follow-up visits (1, 2, and 5 years), 39 study eyes demonstrated NFS by 1 year. Among 263 eyes without any scar (nonfibrotic or fibrotic) at 2 years and with complete data available at the 5-year follow-up examination, 5 (2%) demonstrated NFS by 5 years, whereas 47 (18%) demonstrated FS by 5 years.

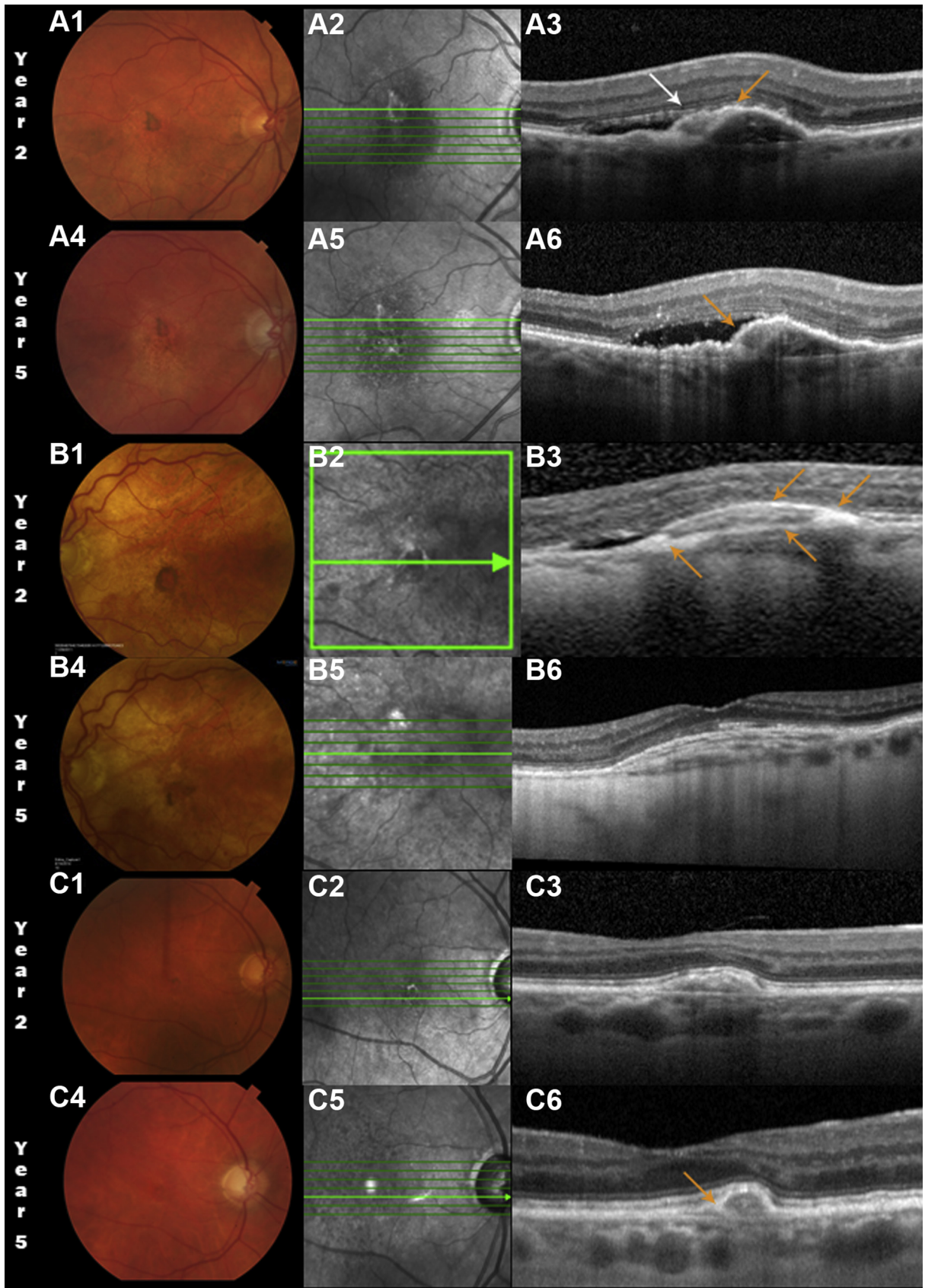
Morphologic changes observed in the 39 eyes in which NFS developed at 1 through 5 years are given in Table 1. Only a small percentage of eyes (5%) demonstrated FS at year 2, but at 5 years, 28% demonstrated FS. Similarly, GA developed in 5% and 21% of eyes at 2 and 5 years, respectively. Nongeographic atrophy was present already in 34% of the eyes at 1 year and increased to

Table 6. Subretinal Hyperreflective Material over Time in Eyes in Which Nonfibrotic Scar, Fibrotic Scar, and No Scar Developed at Year 1

Year 1	Subretinal Hyperreflective Material, No. (%)				P Value*
	Baseline	Year 1	Year 2	Year 5	
Nonfibrotic scar (n = 39)	34 (90)	16 (44)	14 (37)	19 (49)	<0.0001
Fibrotic scar (n = 68)	60 (88)	60 (90)	56 (82)	63 (93)	0.26
No scar (n = 367)	257 (71)	146 (40)	137 (38)	228 (63)	<0.0001
P value <sup>†</sup>	0.001	<0.0001	<0.0001	<0.0001	

\*For the comparison of difference among three time points within a given scar group.

<sup>†</sup>For the comparison of difference among three scar groups.



47% and 65% in years 2 and 5, respectively. Fluorescein leakage, observed in 50% of eyes with NFS at 1 year, decreased to 29% and 20% at years 2 and 5, respectively ( $P = 0.02$ ).

The comparison of the development of accompanying morphologic features among the 3 groups (eyes in which NFS developed at 1 year, FSs developed at 1 year, and no scar developed at 1 year) at each follow-up visit is given in Tables 2, 3, and 4. As shown in Table 2, the number of eyes with GA increased in all 3 groups from 1 to 5 years, but in eyes with NFS at 1 year, the development of GA was the least across all time points ( $P = 0.002$ ). The number of eyes with NGA also increased over time in all the groups but was similar among groups at all time points. The number of eyes with leakage of fluorescein dye decreased over time in all 3 groups but was similar among groups at all time points. The mean baseline total CNV lesion area was 2.3 mm<sup>2</sup> (SD, 2.6 mm<sup>2</sup>), 8.2 mm<sup>2</sup> (SD, 8.8 mm<sup>2</sup>), and 6.3 mm<sup>2</sup> (SD, 6.1 mm<sup>2</sup>) for the NFS group, FS group, and no scar group, respectively ( $P < 0.0001$ ). Mean lesion size increased over time for the 3 types of lesions ( $P < 0.0001$ ), and the mean area for NFS remained the smallest.

Table 3 shows the fluid on OCT over time among the 3 groups. Although the number of eyes with any fluid increased over time in all of the groups, it was not significant in the NFS group ( $P = 0.36$ ). In the NFS group, the individual types of fluid (intraretinal, subretinal, and sub-RPE) also did not show significant variations at 1, 2, or 5 years, and the relative frequency of these 3 types of fluid remained ordered throughout the follow-up period. Intraretinal fluid was present in more eyes in the no scar and FS groups when compared with the NFS group at all follow-up time points. However, more eyes in the NFS group showed subretinal fluid than the other 2 groups at 2 years ( $P = 0.02$ ). We observed sub-RPE fluid in more eyes at all follow-up time points in the group with no scar when compared with the FS and NFS groups. Optical coherence tomography features such as retinal thickness, subretinal fluid thickness, subretinal complex thickness, and total retinal thickness also were not significantly different from baseline at each follow-up time point ( $P > 0.05$ ) in the NFS group (Table 4). However, the mean retinal thickness, subretinal complex thickness, and total retinal thickness grew thinner in the no scar group.

The mean VA over time in eyes that demonstrated NFS at 1 year, in eyes that demonstrated FS at 1 year, and in the eyes with no scar at 1 year is given in Table 5. Eyes with NFS at 1 year demonstrated a VA of 66 letters, 80 letters, 77 letters, and 73 letters at baseline and years 1, 2, and 5, respectively ( $P < 0.0001$ ). In contrast, eyes that demonstrated FS at 1 year demonstrated a mean VA of 54 letters, 61 letters, 63 letters, and 48 letters at baseline, 1, 2, and 5 years, respectively ( $P < 0.0001$ ). In eyes that did not demonstrate either NFS or FS, the mean VA was 65 letters, 73 letters, 72 letters, and 62 letters at baseline and 1, 2, and 5 years, respectively ( $P < 0.0001$ ). Only the NFS group showed a mean VA at 5 years that was better than the VA at baseline, improving from 66 letters (Snellen equivalent, 20/50) to 73 letters (Snellen equivalent, 20/32).

Table 6 shows the percentage of eyes that demonstrated SHRM over time in the 3 groups. Although approximately 90% of eyes showed SHRM at baseline in the NFS and FS groups, only 71% showed baseline SHRM in the no scar group. At 5 years, SHRM was present in 49% of eyes in the NFS group compared with 63% in the no scar group and 93% in the FS group ( $P < 0.0001$ ). At 1 year, 24 eyes with NFS (62%) demonstrated 360° of peripheral pigmentation, 9 eyes (23%) showed almost complete pigmentation ( $>270^\circ$ ), and 6 eyes (15%) showed at least a semicircular pigmentation. The peripheral pigmentation decreased in 8 eyes (21%) at year 2 and in 21 eyes (54%) at year 5, whereas it increased in 6 eyes (15%) at year 5.

## Discussion

Eyes with NFS that developed during the initial year of anti-VEGF treatment evolved over the next 4 years, with changes taking place both in and around the scar. Non-geographic atrophy increased from being present in one third of the eyes at 1 year to being present in nearly half of eyes at 5 years. Geographic atrophy, which was not present in any eyes with NFS at 1 year, developed in 21% of eyes by 5 years. This increased incidence of GA is relatively modest when compared with the more substantial percentage of eyes with FS at 1 year that later demonstrated GA.<sup>12</sup> The appearance of new FS in color images was observed at year 5 in one fourth of the eyes with NFS, with most cases occurring between years 2 and 5. This later appearance may have been the result of the absence of strict oversight of trial conditions during this period, which may have resulted in undertreatment or simply may have been the result of the natural history of the disease.

We reported previously that approximately 20% of eyes in CATT demonstrated NFS by 2 years.<sup>18</sup> The development of NFS is relatively uncommon after the initial 2 years of therapy, with an incidence of less than 2% between years 2 and 5. In contrast, the incidence of FS was 18% during this period. The results of the 5-year follow-up of CATT participants suggest that almost all of the NFSs form within 2 years of starting anti-VEGF therapy for nAMD. Their occurrence was scarce after this period, although the strict oversight of trial conditions was absent.

Although some risk factors such as classic CNV and SHRM at baseline are common to both NFS and FS, they differ in their presentation on color images, visual outcomes, types of retinal fluid seen on OCT, and changes to SHRM during follow-up. Nonfibrotic scar, described more

**Figure 2.** Color fundus photographs (left column), infrared scanning laser ophthalmoscopic (IR SCO) images (center column), and spectral-domain OCT images (right column) showing nonfibrotic scar (NFS) in 3 Comparison of Age-Related Macular Degeneration Treatments Trials participants at years 2 and 5. **A1, B1, C1,** A small pigment-encircled NFS was seen at 2 years that (**A4, B4, C4**) was diminished at year 5. **A2, B2, C2,** Pigmented areas appear bright on the IR SLO images. **A3, A6,** Spectral-domain OCT images showing compact subretinal hyperreflective material (SHRM; white arrow) over the fibrovascular pigment epithelial detachment (PED) with adjacent subretinal fluid (SRF). However, there is a hyperreflective layer extending from the retinal pigment epithelium (RPE) across part of the inner border of the SHRM (orange arrow). By year 5, the SHRM was encased in the RPE layer contiguous with the inner border of the PED and subretinal fluid persisted with focal sites of greater penetration of OCT signal into the choroid. **B1, B2, B3,** Nonfibrotic scar at 2 years in another study eye along with a similar appearance as in the previous eye (**A3**) but with an even more prominent region of heaped-up hyperreflectivity corresponding to the sites of the dark pigment ring and a second RPE layer extending across the SHRM. However, the SHRM has either resolved or cannot be distinguished from (**B6**) the layered reflectance in the fibrovascular PED, and the SRF has resolved. **C1, C2, C3,** In the third example, (**C3**) the year 2 compact SHRM contracts further at year 5, (**C6**) with a more pronounced hyperreflective RPE layer over the lesion.



comprehensively in an earlier article,<sup>18</sup> has no raised yellowish mounds of FS tissue on stereo color images. The mean SHRM thickness at baseline in eyes that subsequently demonstrate NFS by 2 years has been reported to be 148  $\mu\text{m}$ , which is larger than the SHRM thickness in eyes that do not demonstrate any scar (119  $\mu\text{m}$ ) but less than the SHRM thickness in eyes that demonstrate FS (168  $\mu\text{m}$ ).<sup>19</sup> At 5 years, the frequency of SHRM was reduced by 40% in eyes with NFS when compared with their presence at baseline. In contrast, the no scar group showed a reduction of only 9%, although the baseline eyes showed the lowest frequency of SHRM among the 3 groups, and the FS group showed the highest frequency of SHRM and did not show any appreciable reduction in frequency during follow-up. It seems that the SHRM in some eyes with NFS begins compacting and disappearing, similar to the example shown in Figure 2, where the SHRM appears to become thin on the follow-up OCT scans obtained at years 2 and 5. The layers of scar tissue seen in the same example remain confined under the elevated pigment epithelial detachment.

Unlike the FS group and the no scar group, the frequency of any fluid on OCT remained constant at all follow-up time points in the NFS group. The frequency of individual types of fluid on OCT (intraretinal, subretinal, and sub-RPE) also did not fluctuate significantly in the NFS group. However, the NFS group showed less intraretinal fluid than the other groups at both baseline and follow-up. Conversely, although not reaching a significant difference except at year 2, subretinal fluid was present in a larger proportion of eyes in the NFS group compared with the other groups. The no scar group showed a higher frequency of sub-RPE fluid compared with the other groups, and this may be related to the large number of occult lesions in this group, which anatomically lie below the RPE layer and do not enter the sub-RPE layer. The various mean retinal measurements also remained constant in NFS group throughout the follow-up period, in contrast to the other groups.

Despite the continued evolution of NFS over 5 years, VA remained remarkably good at a mean of 73 letters (Snellen equivalent, 20/32) and was better than the 5-year mean VA in eyes that showed FS at 1 year (48 letters; Snellen equivalent, 20/100) and better than eyes that did not show a scar at 1 year (62 letters; Snellen equivalent, 20/63). Many factors could contribute to the good vision observed in the NFS group: smaller CNV lesions, the reduced frequency and size of GA,<sup>16,17</sup> the reduced frequency and thinning of SHRM,<sup>22</sup> the lower frequency of intraretinal fluid that is known to cause more retinal destruction and reduction of vision,<sup>23</sup> and the higher frequency of eyes with subretinal fluid that is known to be associated with better VA and smaller areas of GA.<sup>24</sup>

The pigment ring of the NFS is not well understood. It is most likely the result of multilayering of migrating RPE cells best seen on OCT (Fig 2B3) at both edges of the pigment epithelial detachment. The splitting is most apparent on the left side. In each of these cases (Fig 2), RPE encasing the

CNV is apparent and may explain the process that limited the enlargement of these lesions. At the edges, the RPE is not yet stretched thin, so it still appears dark, but in the center of the lesion, it appears lighter because the RPE cells have stretched, diluting their pigment. The hypopigmentation also could be the result of replicating RPE cells that fill in for dead RPE cells, halving the pigment with each replication. Histopathologic studies of eyes with NFS may help us to understand better this phenotypic presentation.

Limitations of this study include the relatively small number of eyes with NFS at 1 year that were followed up through 5 years and the lack of availability of spectral-domain OCT at baseline and 1 year. Despite these limitations, it is apparent that the development of an NFS is far more preferable than the development of an FS. Nonfibrotic scars tend to maintain better VA over time and develop far fewer destructive pathologic changes than an FS. Better understanding of NFSs and how and why they differ from FSs may lead to the identification of future therapeutic targets that reduce fibrosis and scar formation.

## References

1. CATT Research Group, Martin DF, Maguire MG, Ying GS, et al. Ranibizumab and bevacizumab for neovascular age-related macular degeneration. *N Engl J Med*. 2011;364:1897–1908.
2. IVAN Study Investigators, Chakravarthy U, Harding SP, et al. Ranibizumab versus bevacizumab to treat neovascular age-related macular degeneration: one-year findings from the IVAN randomized trial. *Ophthalmology*. 2012;119:1399–1411.
3. Brown DM, Kaiser PK, Michels M, et al. Ranibizumab versus verteporfin for neovascular age-related macular degeneration. *N Engl J Med*. 2006;355:1432–1444.
4. Rosenfeld PJ, Brown DM, Heier JS, et al. Ranibizumab for neovascular age-related macular degeneration. *N Engl J Med*. 2006;355:1419–1431.
5. Berg K, Pedersen TR, Sandvik L, Bragadóttir R. Comparison of ranibizumab and bevacizumab for neovascular age-related macular degeneration according to LUCAS treat-and-extend protocol. *Ophthalmology*. 2015;122:146–152.
6. Garweg JG, Zirpel JJ, Gerhardt C, Pfister IB. The fate of eyes with wet AMD beyond four years of anti-VEGF therapy. *Graefes Arch Clin Exp Ophthalmol*. 2018;256:823–831.
7. Munk MR, Ceklic L, Ebnetter A, et al. Macular atrophy in patients with long-term anti-VEGF treatment for neovascular age-related macular degeneration. *Acta Ophthalmol*. 2016;94:757–764.
8. Comparison of Age-Related Macular Degeneration Treatments Trials (CATT) Research Group. Five-year outcomes with anti-vascular endothelial growth factor treatment of neovascular age-related macular degeneration: the Comparison of Age-Related Macular Degeneration Treatments Trials. *Ophthalmology*. 2016;123:1751–1761.
9. Gillies MC, Campain A, Barthelmes D, et al. Long-term outcomes of treatment of neovascular age-related macular degeneration: data from an observational study. *Ophthalmology*. 2015;122:1837–1845.



10. Peden MC, Suñer IJ, Hammer ME, Grizzard WS. Long-term outcomes in eyes receiving fixed-interval dosing of anti-vascular endothelial growth factor agents for wet age-related macular degeneration. *Ophthalmology*. 2015;122:803–808.
11. Rofagha S, Bhisitkul RB, Boyer DS, et al. Seven-year outcomes in ranibizumab-treated patients in ANCHOR, MARINA, and HORIZON: a multicenter cohort study (SEVEN-UP). *Ophthalmology*. 2013;120:2292–2299.
12. Daniel E, Pan W, Ying GS, et al. Development and course of scars in the Comparison of Age-Related Macular Degeneration Treatments Trials. *Ophthalmology*. 2018;125:1037–1046.
13. Channa R, Sophie R, Bagheri S, et al. Regression of choroidal neovascularization results in macular atrophy in anti-vascular endothelial growth factor-treated eyes. *Am J Ophthalmol*. 2015;159:9–19.
14. Jaffe GJ, Martin DF, Toth CA, et al. Macular morphology and visual acuity in the comparison of age-related macular degeneration treatments trials. *Ophthalmology*. 2013;120:1860–1870.
15. Grunwald JE, Pistilli M, Daniel E, et al. Incidence and growth of geographic atrophy during 5 years of Comparison of Age-Related Macular Degeneration Treatments Trials. *Ophthalmology*. 2017;124:97–104.
16. Grunwald JE, Pistilli M, Ying GS, et al. Growth of geographic atrophy in the Comparison of Age-Related Macular Degeneration Treatments Trials. *Ophthalmology*. 2015;122:809–816.
17. Grunwald JE, Daniel E, Huang J, et al. Risk of geographic atrophy in the Comparison of Age-Related Macular Degeneration Treatments Trials. *Ophthalmology*. 2014;121:150–161.
18. Daniel E, Toth CA, Grunwald JE. Risk of scar in the Comparison of Age-Related Macular Degeneration Treatments Trials. *Ophthalmology*. 2014;121:656–666.
19. Casalino G, Stevenson MR, Bandello F, Chakravarthy U. Tomographic biomarkers predicting progression to fibrosis in treated neovascular age-related macular degeneration: a multimodal imaging study. *Ophthalmol Retina*. 2017;5:451–461.
20. Grunwald JE, Daniel E, Ying GS, et al. Photographic assessment of baseline fundus morphologic features in the Comparison of Age-Related Macular Degeneration Treatments Trials. *Ophthalmology*. 2012;119:1634–1641.
21. Folgar FA, Jaffe GJ, Ying GS, et al. Comparison of optical coherence tomography assessments in the Comparison of Age-Related Macular Degeneration Treatments Trials. *Ophthalmology*. 2014;121:1956–1965.
22. Willoughby AS, Ying GS, Toth CA, et al. Subretinal hyperreflective material in the Comparison of Age-Related Macular Degeneration Treatments Trials. *Ophthalmology*. 2015;122:1846–1853.
23. Shah N, Maguire MG, Martin DF, et al. Angiographic cystoid macular edema and outcomes in the Comparison of Age-Related Macular Degeneration Treatments Trials. *Ophthalmology*. 2016;123:858–864.
24. Sharma S, Toth CA, Daniel E, et al. Macular morphology and visual acuity in the second year of the Comparison of Age-Related Macular Degeneration Treatments Trials. *Ophthalmology*. 2016;123:865–875.

## Footnotes and Financial Disclosures

Originally received: September 4, 2018.

Final revision: November 14, 2018.

Accepted: November 19, 2018.

Available online: November 23, 2018. Manuscript no. 2018-1971.

<sup>1</sup> Scheie Eye Institute, University of Pennsylvania, Philadelphia, Pennsylvania.

<sup>2</sup> Department of Ophthalmology, Duke University, Durham, North Carolina.

<sup>3</sup> National Eye Institute, National Institutes of Health, Bethesda, Maryland.

<sup>4</sup> Cole Eye Institute, Cleveland Clinic, Cleveland, Ohio.

Presented at: Association for Research in Vision and Ophthalmology Annual Meeting, Honolulu, Hawaii, May 2018.

Financial Disclosure(s):

The author(s) have made the following disclosure(s): G.Y.: Consultant – Chengdu Kanghog Biotech Co. Ltd., Ziemer Ophthalmic Systems AG, Synergy Research.

B.J.K.: Consultant – Allergan, Synergy Research.

C.A.T.: Royalties – Alcon (through Duke University).

F.F.: Consultant – Foundation for Fighting Blindness, Janssen Research & Development, LLC, Viewpoint Therapeutics, Inc., EMMES, Acuela, Apellis, SemaThera, PTC Therapeutics, Bausch and Lomb; Patent/Royalties: AMD Supplements; Data and Safety Monitoring Committee – Allergan, Genentech/Roche, Novartis, Nordisk; Executive committee – Diabetic Retinopathy Clinical Research Network.

G.J.J.: Consultant – Heidelberg Engineering, Alcon/Novartis, Genentech/Roche, Neurotech.

M.G.M.: Data and safety monitoring committee – Genentech/Roche.

Supported by the National Eye Institute, National Institutes of Health, Bethesda, Maryland (cooperative agreement nos.: U10 EY017823, U10 EY017825, U10 EY017826, U10 EY017828, and R21EY023689 for the

ClinicalTrials.gov study NCT00593450). The funding organization had no role in the design or conduct of this research.

**HUMAN SUBJECTS:** Human subjects were included in this study. The human ethics committees associated with each center approved the study. All research complied with the Health Insurance Portability and Accountability (HIPAA) Act of 1996. All research adhered to the tenets of the Declaration of Helsinki. The complete list of IRBs are from the participating institutions listed in the CATT credit roster (available online at [www.aojournal.org](http://www.aojournal.org)). All participants provided informed consent.

No animal subjects were included in this study.

**Author Contributions:**

Conception and design: Daniel, Maguire

Analysis and interpretation: Daniel, Ying, Kim, Toth, Ferris, Martin, Grunwald, Jaffe, Dunaief, Pan, Maguire

Data collection: Ying, Kim, Toth, Ferris, Martin, Grunwald, Jaffe, Maguire

Obtained funding: Daniel, Kim, Toth, Ferris, Jaffe, Maguire

Overall responsibility: Daniel, Ying, Kim, Toth, Ferris, Martin, Grunwald, Jaffe, Dunaief, Pan, Maguire

**Abbreviations and Acronyms:**

**CATT** = Comparison of Age-related Macular Degeneration Treatments Trials; **CFP** = color fundus photograph; **CNV** = choroidal neovascularization; **FA** = fluorescein angiography; **FS** = fibrotic scar; **GA** = geographic atrophy; **nAMD** = neovascular age-related macular degeneration; **NFS** = nonfibrotic scar; **NGA** = nongeographic atrophy; **RPE** = retinal pigment epithelium; **SD** = standard deviation; **SHRM** = subretinal hyperreflective material; **VA** = visual acuity; **VEGF** = vascular endothelial growth factor.

**Correspondence:**

Ebenezer Daniel, MBBS, PhD, Scheie Ophthalmology Reading Center, University of Pennsylvania, 3535 Market Street, Suite 700, Philadelphia, PA 19104. E-mail: [ebdaniel@penmedicine.upenn.edu](mailto:ebdaniel@penmedicine.upenn.edu).